


# Surgical Prosthodontics—A Shift in Patient Treatment at the University of Tennessee Graduate Prosthodontic Program (Case Report)

Sanjay Karunagaran, B.D.S., D.D.S., M.S.D., Jonathon Egbert, D.D.S.,  
Andrew Johnson, D.D.S., M.D.S., F.A.C.P., C.D.T., and Sony C Markose, B.D.S., D.D.S., M.S.D.



## Introduction

As an increasing number of Graduate Prosthodontic Programs begin to introduce surgical expectations and requirements into their educational curriculum, implant manufacturers have also begun to make surgical placement protocols more user friendly to the clinician. Recently, computer-guided surgeries for implant placement using stereolithographic templates are gaining popularity. Here at the University of Tennessee Graduate Prosthodontic Program, it has been used successfully in recent years. The benefit of such a surgical protocol is that it enables the clinician to perform a minimally invasive procedure that has several advantages: accuracy of the implant placement, predictability of the surgery, reduced post-surgical discomfort and a reduction in the time needed for the final rehabilitation.<sup>1,2</sup> This predictable procedure also allows the clinician to provide their treatment “in-house” and has therefore gained popularity among prosthodontists.

The successful placement of dental implants in the posterior maxilla can often be challenging, due to the compromised and atrophic nature of available bone. The vertical dimension of alveolar bone as measured from the crest of the alveolar ridge to the base of the maxillary sinus is often limited. This vertical ridge insufficiency may be the result of resorption subsequent to extractions, trauma or pathology, and is often compounded by pneumatization of the maxillary sinuses. A minimum of 10 mm of vertical bone height is recommended to obtain predictable implant success.<sup>3</sup> The lack of available space for an adequately sized implant should be cause to consider additional procedures which can compensate for such alveolar deficits.

To overcome this anatomic limitation, sinus augmentation procedures have been developed that enable implant

## ABSTRACT

Over recent years Dentistry has evolved, and as such, we have been able to make strides in restoring edentulous patients with dental implants. Recently, the specialty of Prosthodontics, in addition to the prosthetic rehabilitation of complex dental patients with fixed, removable, implant, and cosmetic dental needs, has begun to shift into the surgical realm of patient treatment. Report outlines a minimally invasive technique for sinus floor elevation, on the controlled use of drills and osteotomes, while simultaneously placing implants through a guided protocol. The rationale for such a technique is that it provides a predictable and repeatable method of attaining vertical ridge augmentation as well as correct implant placement in order to obtain ideal restorative reconstructions. In addition it provides the dentist with the autonomy to treat patients requiring implants from start to completion with a great deal of control. Postoperative radiographs reveal the amount of vertical height gained and concomitant implant placements.

### Keywords:

Transcrestal, Sinus elevation, Guided implants, Stereolithographic guide

placement in previously deficient sites.<sup>4,5</sup> The elevation of the sinus membrane and the addition of grafted bone are usually accomplished by either a direct (lateral window) approach popularized by Tatum, or an indirect (transcrestal) approach presented by Summers. The most frequently used technique in SFE (sinus floor elevation) is the lateral window was presented by Tatum, which has had long term success.<sup>6</sup> The less invasive procedure for sinus elevation by Summers uses root analog instruments to elevate the Schneiderian membrane from a transcrestal approach without the need for a lateral window

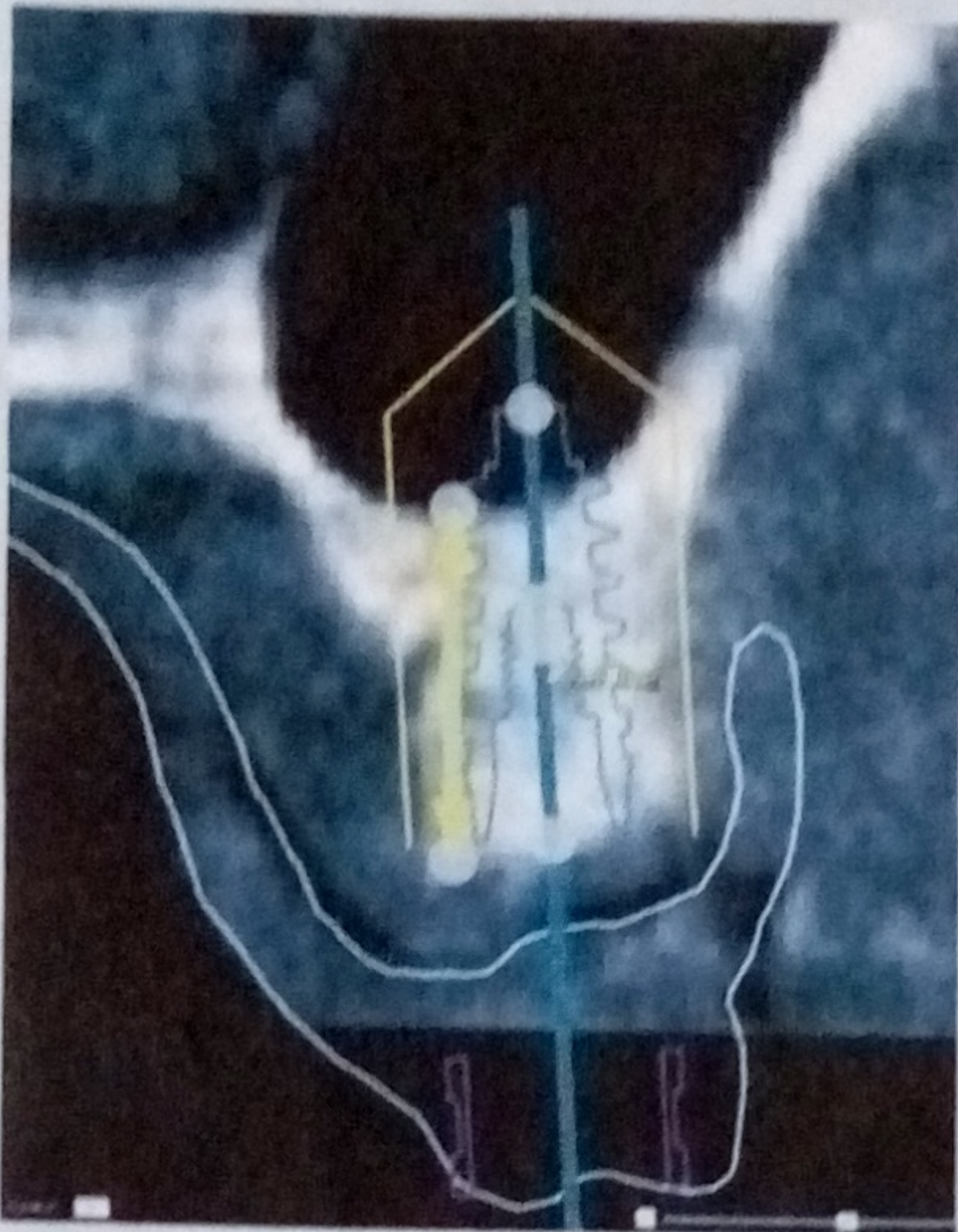
The indirect sinus lift or sinus intrusion osteotomy represents a technique which attempts to vertically enhance bone through an antral access created through the implant osteotomy. The technique traditionally involves the up-fracture (by means of osteotomes) of the residual sinus floor at the depth of a partially prepared implant site and providing an atraumatic access point for graft material and implant insertion inferior to the intact Schneiderian

membrane. The membrane is then displaced superiorly and laterally to the necessary extent by the condensation of graft material through the osteotomy into the negative space created as the membrane is dissected.<sup>7</sup>

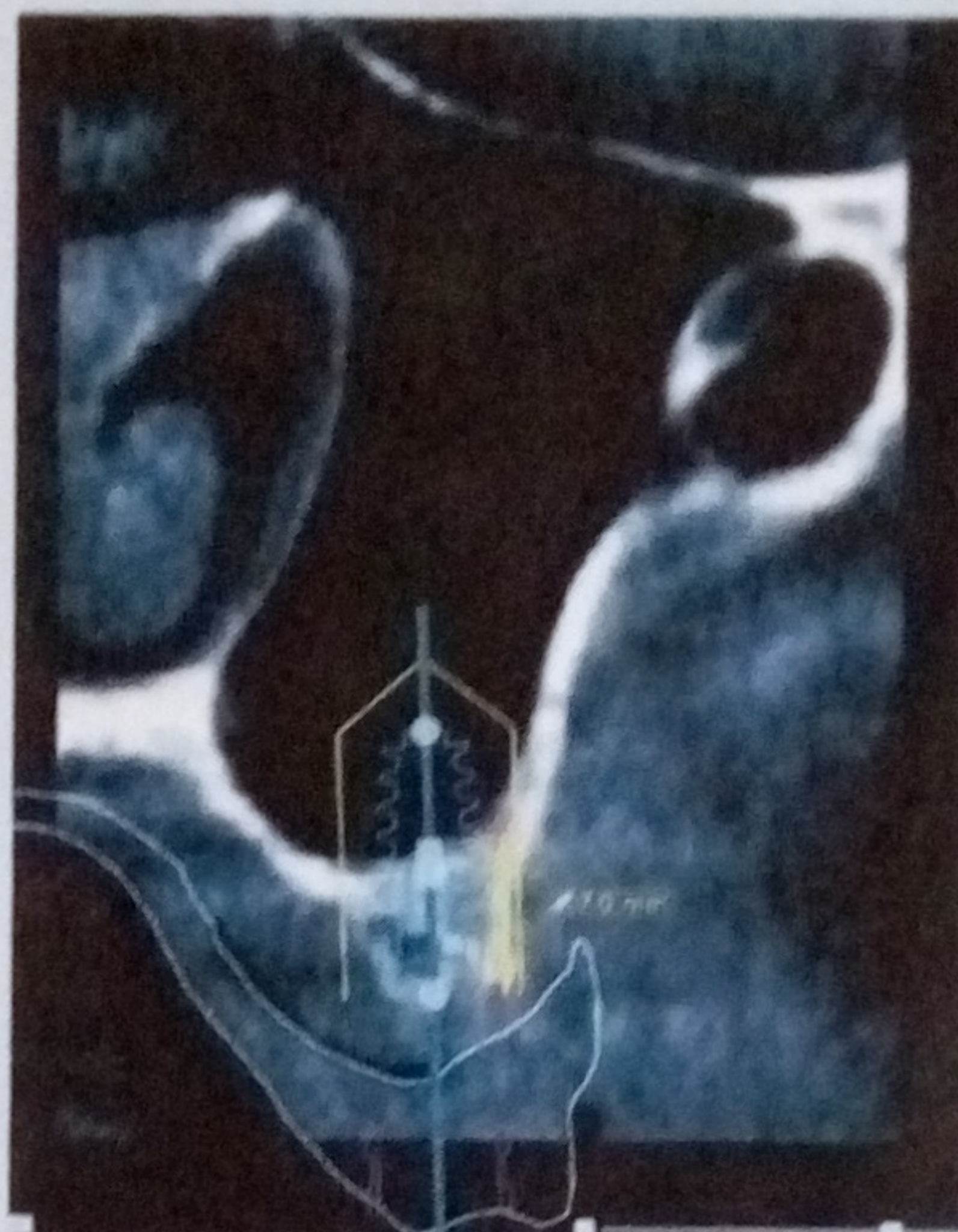
The primary advantage of transcrestal approach is arguably its minimal invasiveness. Considering the necessary incisions are in no way expanded beyond what is necessary for simple implant placement, the post-operative morbidity is greatly reduced. However, the quantity of bone that can be gained is often less than that achievable through the direct technique, and some authors have suggested a lateral approach is more prudent in patients with severely resorbed maxillas.<sup>8,9</sup> Also, the indirect method is limited in that it carries more potential for undiagnosed membrane perforations due to visibility constraints, and if a membrane rupture is suspected, this technique offers little surgical access to treat the defect.

This article describes a technique of accomplishing an indirect maxillary sinus graft using a flapless transcrestal


**Figure 1: Preoperative cross-sectional view of planned implant placement located at implant site #3 (Right maxillary sinus).**



**Figure 2: Preoperative cross-sectional view of planned implant placement located at implant site #14 (Left maxillary sinus).**



**Figure 3: Frontal view of CAD surgical guide showing implant positions and anchor pins used for fixation of surgical guide.**



entry in conjunction with a CAD-CAM stereolithographic surgical template using osteotomes through the implant guide sleeves.

Each implant manufacturer has their own protocol for the guided implant surgery, and variations do exist in the methods of surgical template design and fabrication. The guided surgery system presented here (NobelClinician and NobelGuide, Nobel Biocare, Yorba Linda, California) begins with the creation of a carefully developed radiographic scanning template which becomes the basis for the virtual implant planning process and surgical guide construction.

### Technique

#### Diagnostic Protocol

A 49-year-old male patient presented to graduate prosthodontic clinic for a diagnostic work up and treatment plan. An evaluation of his dental and medical history revealed no medications or systemic diseases that would have contraindications to dental treatment. A comprehensive treatment plan was developed, and all treatment options were presented to the patient. The patient opted for an implant-supported fixed prosthesis in the maxilla.

Properly extended maxillary and

mandibular diagnostic impressions were made and articulated at the proposed Vertical Dimension of Occlusion as part of the diagnostic phase. The patient's residual ridge morphology was assessed to determine the presence of anatomical landmarks, vestibular depth, tori, redundant and mobile tissue. An analysis of the maxillomandibular relationship was accomplished to determine the proposed outcome of the prosthetic rehabilitation and then reconfirmed at the trial set up and tries in stage. Any conditions requiring preprosthetic surgery were outlined at this stage and incorporated into the prescribed surgical treatment. Such additional surgical needs included minor soft and hard tissue corrections, grafting procedures, correction of dentofacial deformities, hard tissue augmentation, and major soft tissue revisions. Interarch space was also assessed, in addition to the parallelism of the opposing ridges. These preliminary data provides the information necessary to begin the prosthetic rehabilitation.

A proposed tooth try-in was conducted to confirm that the final prostheses and address patient needs and expectations. This included the establishment of the ideal tooth position, lip support, phonetics, esthetics, and vertical dimension of occlusion. Following the

approval of this trial set-up, fabrication of the radiographic guide was initiated.

#### Radiographic Guide Protocol

With the introduction of digital systems, the three-dimensional data information of bone has allowed us to plan for our implant placement more precisely. This allows anatomical boundaries to be carefully considered, while planning our ideal prosthetic end goal.<sup>10</sup> The assessment of the intended surgical site is accomplished by three-dimensional data that is recovered from a computerized tomography (CT) scan that is converted into a DICOM (Digital Imaging and Communications in Medicine) format. This format enables the information obtained to be imported into an implant planning software that can then be analyzed in planning the fabrication of the final surgical template. Such templates are constructed in a stereolithographic fashion by using digital data and integrating this information to produce the appropriate surgical sleeves for correct implant positioning. This procedure allowed us to plan for the location and amount of bone graft needed in our final tissue supported surgical template. The radiographic template was fabricated using our projected maxillary tooth contours to obtain prosthetically

driven implant placement protocols.

Care in the fabrication of our radiographic guide was paramount, and the scan protocol was followed as outlined by Nobel Biocare. First, the trial tooth setup was duplicated in clear acrylic ensuring that a sufficient thickness of material was duplicated in the prosthesis (2.5mm – 3 mm). The buccal flanges of the template required sufficient vestibular extension for placement of gutta percha markers and were also needed to duplicate this extension in support for the guided anchor pins during the surgical phase. The fit of this radiographic template was tried in intraorally to determine its accuracy, and if required, a hard reline is established at this stage to provide stability, support and retention for the guide. Radiographic makers were placed, half on the lingual and half on the buccal cameo surfaces of the prosthesis. Spherical marker placement was accomplished at varying horizontal planes, below the gingival surfaces of the teeth using a number eight round bur to a depth of 1 mm and filled in flush to the surface. At the try-in appointment, a full arch bite registration was made with radiolucent PVS bite registration material. The patient was then scanned using Kodak 9500 Cone beam 3D System (Carestream Health, Inc.) with template in mouth. A solo scan of template was performed followed by a patient scan. The DICOM sets were then uploaded onto Nobel Clinician. The case planning was then initiated with the NobelClinician Software.

#### Implant Planning Protocol

The axial, coronal, and sagittal images from the software were examined. The axial slice is similar to an occlusal radiograph and outlines the buccolingual width of bone and establishes the planned implant platform diameter. The coronal slice establishes bone volume, quality and provides information on anatomical limitations both in a buccolingual and apicoronal direction. Implant placement planning was then adjusted directionally in relation to the tooth position within the boundaries of the prosthetic envelope (Figures 1, 2). The sagittal views provided information on location of the maxillary sinuses. Six maxillary implants 4.3 mm x 11.5 mm were planned (Nobel Active, Nobel Biocare, AG,

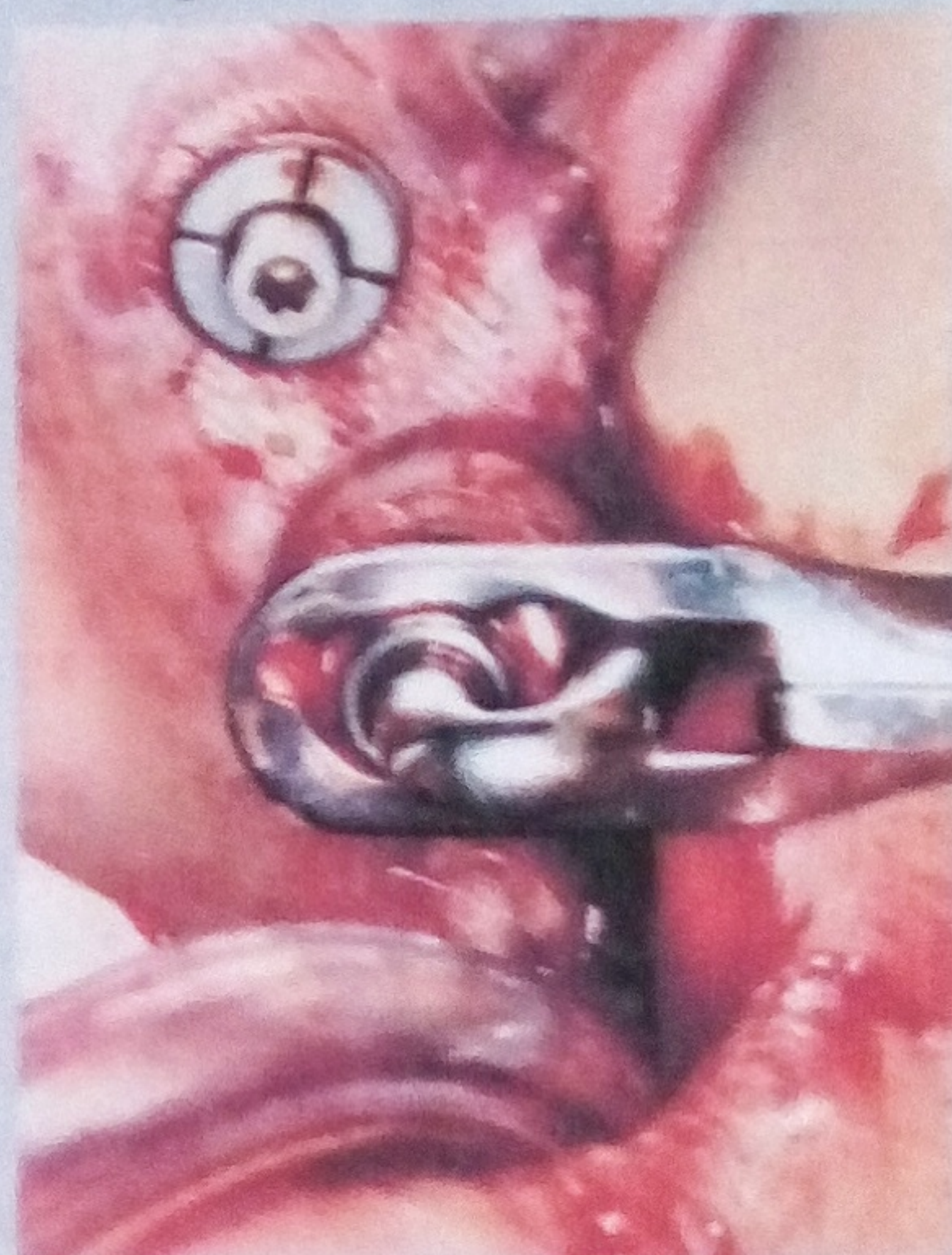Zurich, Switzerland) along with the size of the intended sinus elevation. (Figure 3)

Once the implants were planned, the information was transmitted to Nobel Biocare for the construction of the surgical template. The template was constructed from the information provided by the radiographic guide and contained metallic sleeves which corresponded to the size, location and the projected angle of the planned implants as determined by the implant planning software.

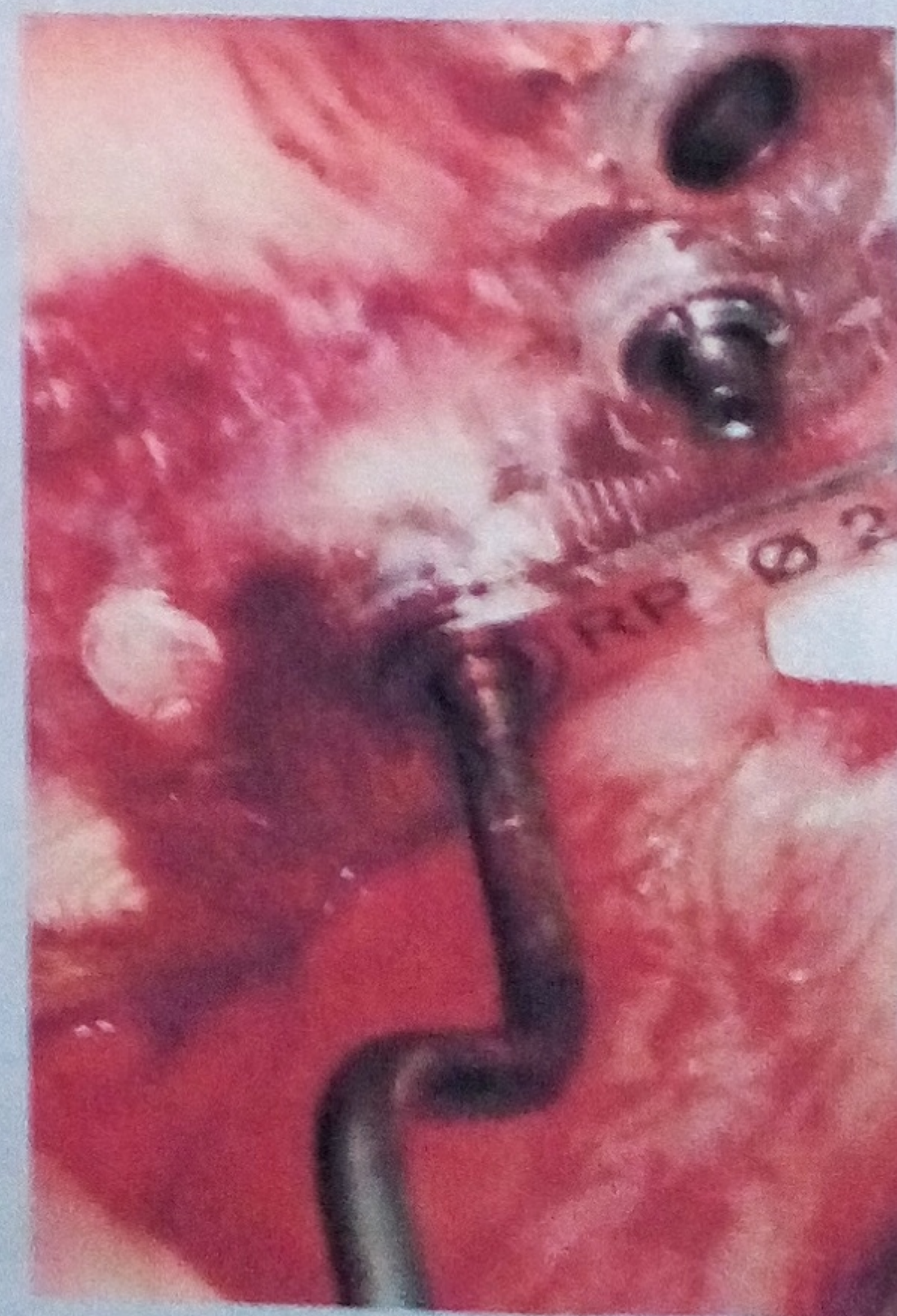#### Surgical Protocol

During this phase, two grams of Amoxicillin and 800mg Ibuprofen were dispensed one hour prior to the surgical procedure. The procedure was performed under local anesthesia and the Surgical Guide was placed using anchor pins (1.5x10) per manufacturers specifications. The surgical template was checked for seating accuracy and seated in place with the aid of the previously constructed interocclusal record and by stabilization pins. The stabilization of the surgical template is an important phase in the surgical protocol as its accurate seating establishes the correct placement of the implants as planned in the radiographic protocol phase. Once this had been completed, a flapless surgical approach was initiated. Osteotomies were performed under copious amounts of irrigation at 1200 rpm per manufacture specifications. Osteotomies were prepared the width, and 1mm short of maxillary sinus floor to depths of 8mm (right) and 6mm (left). An osteotome indirect sinus lift technique was performed the guide, utilizing guide sleeves and light tapping with mallet through condensing osteotomes. The sinus floor was then up-fractured (in the last 1mm) using osteotomes and a sterile amalgam carrier used (Figure 4) to deliver .25cc of allograft bone substitute (Parous Particulate Cortico-cancellous Zimmer®). Then osteotomes were tapped to the length, delivering the bone to the sinus and simultaneously elevating the Schneiderian membrane (Figure 5). This technique was repeated until 1.0 cc of bone was delivered to each site. The implants were then subsequently placed, achieving 50Ncm of insertion torque. Cover screws were placed and

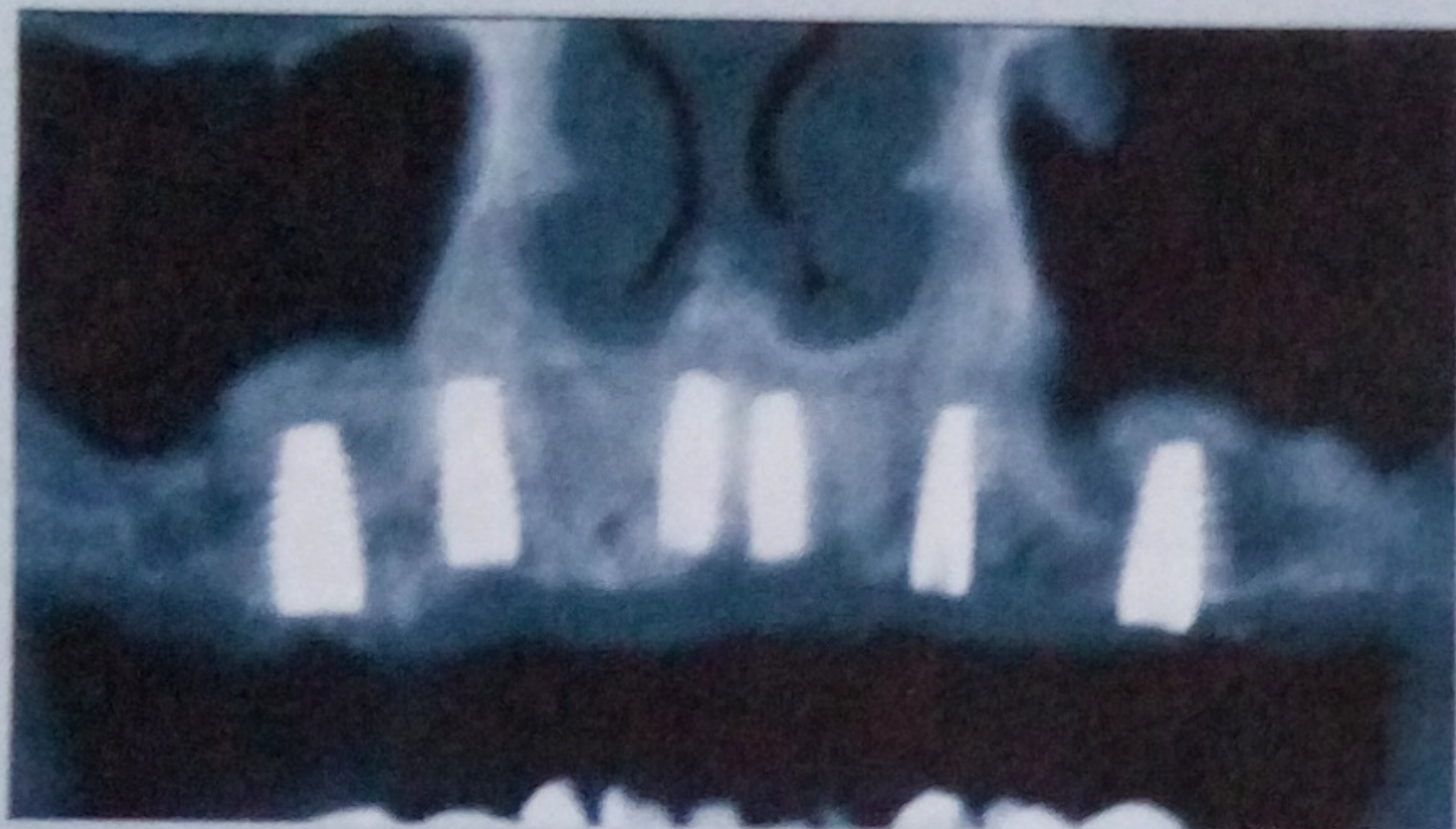
**Figure 4: Intraoperative photograph showing allograft particulate being added through surgical guide sleeve during crestal approach sinus augmentation using sterile amalgam carrier.**



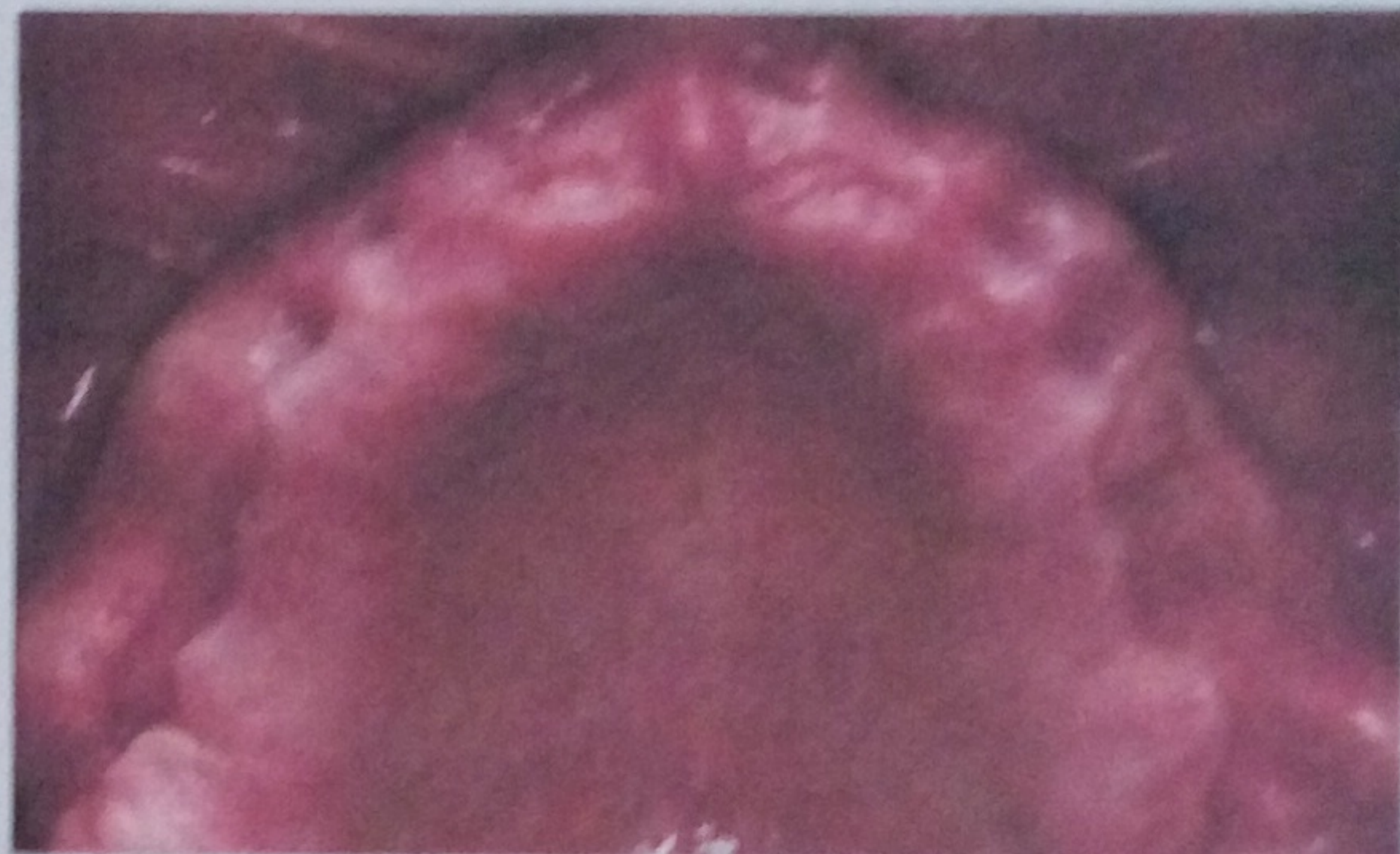
**Figure 5: Intraoperative photograph showing crestal approach using a guided osteotome technique to up-fracture the antral floor of the maxillary sinus and increase vertical osseous height of the sinus.**



**Figure 6: Postoperative frontal view of CBCT following guided indirect sinus augmentation and placement of six maxillary implants.**



**Figure 7: Postoperative maxillary occlusal view following proper healing period.**



post-operative scan accomplished, which revealed the degree of sinus membrane elevation and amount of grafted bone. The interim maxillary prosthesis was then placed with adequate relief, and the patient was instructed not to use their mandibular prosthesis for two weeks.

#### **Post Operative Protocol**

The patient was provided with a Chlorhexidine (CHX) rinse for 1 week. In addition, a prescription for Keflex 500mg three times a day for 10 days, Ibuprofen 800mg three times a day for 3 days, and Lortab 5/500, Diphenhydramine was given. The patient was then seen at a one and two week recall appointment which revealed no dehiscence or pathology from the surgical procedure.

A postoperative panoramic radiograph was taken of the implant sites (Figure 6).


#### **FINAL OUTCOMES**

In many instances these changes in Prosthodontics have allowed patients with fully edentulous handicaps (Figure 7) to be completely rehabilitated with their missing dentition with fixed implant supported restorations (Figures 8, 9).

#### **Conclusion**

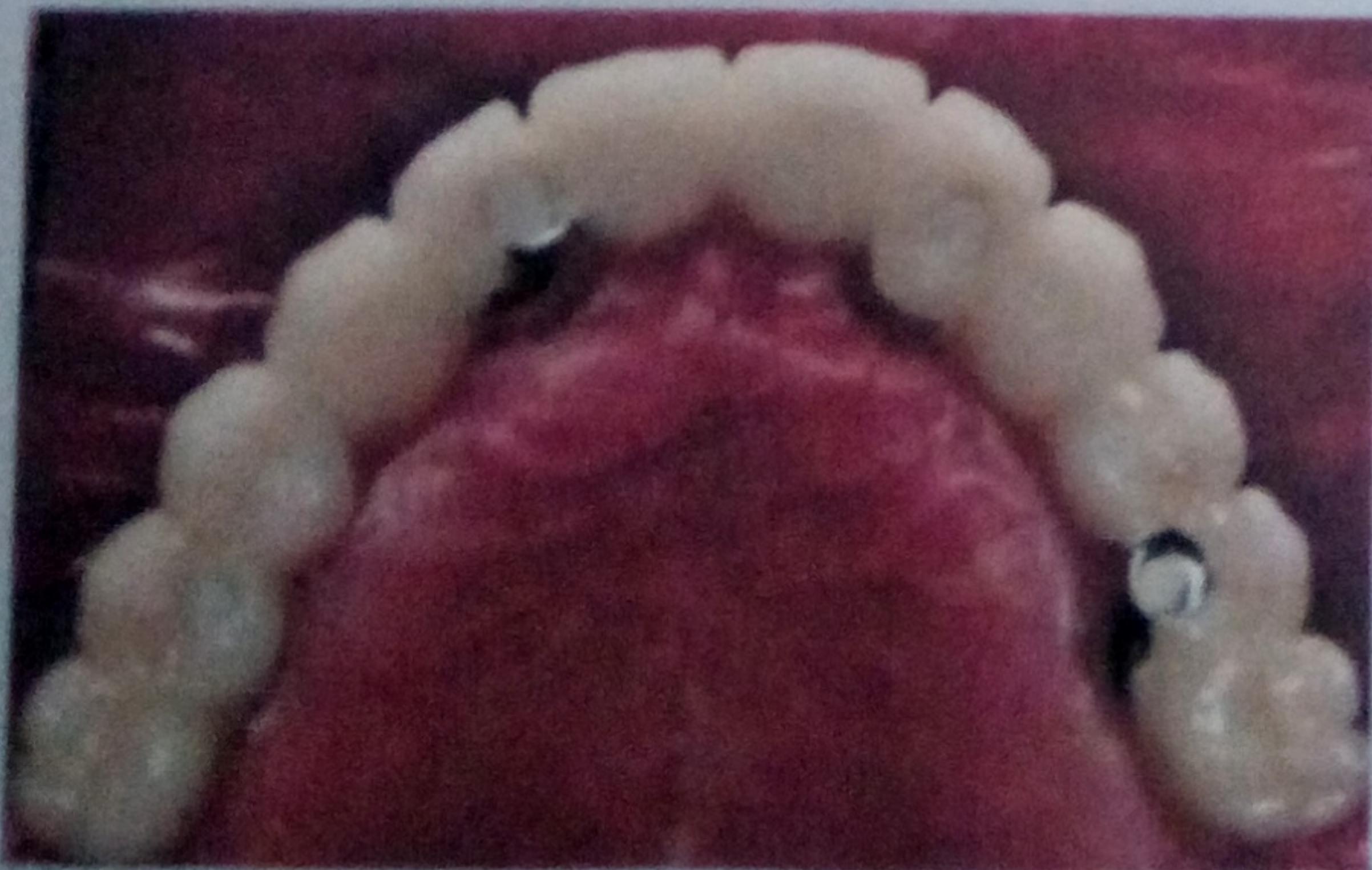This article outlines a method to elevate the maxillary sinus through a transcresal approach along with simultaneous placement of the implant using a computer guided approach. The transcresal approach has been shown to produce a more predictable approach

for implant placement in regions that may prove to have anatomical sinus limitations. This approach allows safe membrane elevation without perforation in combination with higher implant stability at placement. The guided approach provides accurate implant placement in relation to the planned surgical planning protocol. It helps establish implant placement and grafting requirements, prior to beginning the surgical phase of treatment. This allows better risk management and allows non-surgical clinicians to begin to manage and treat their patients with more confidence

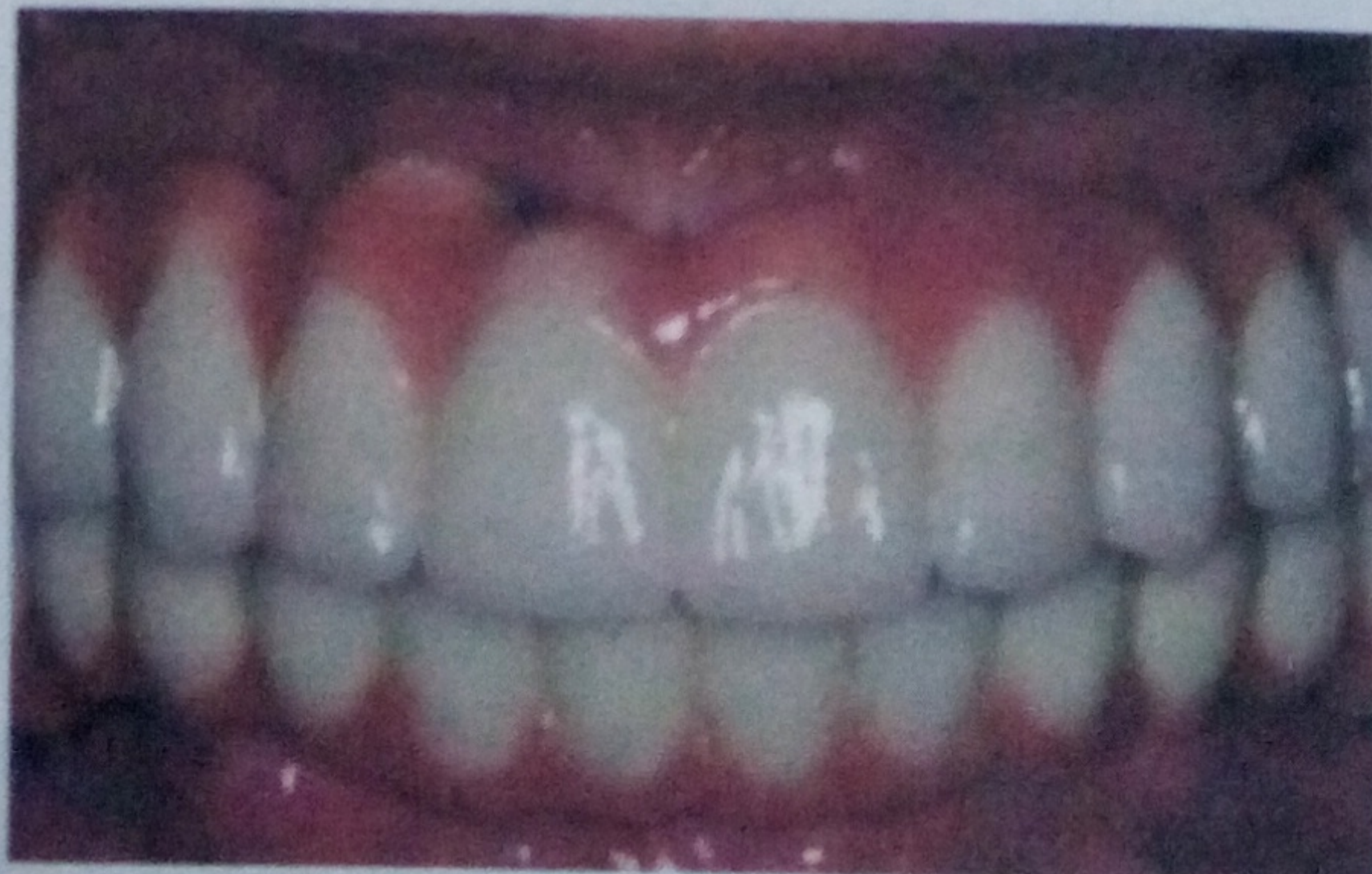

*Disclosure:* The authors did not report any disclosures.

**Figure 8: Postoperative maxillary occlusal view of definitive maxillary implant supported fixed prosthesis.**



**Figure 9: Frontal view of definitive maxillary and mandibular implant supported fixed prostheses.**



## References:

1. Eggers, G., E. Patelis, and J. Muhling. Accuracy of template-based dental implant placement. *Int J Oral Maxillofac Implants*, 2009. 24(3): p. 447-54.
2. Widmann, G. and R.J. Bale. Accuracy in computer-aided implant surgery—a review. *Int J Oral Maxillofac Implants*, 2006. 21(2): p. 305-13.
3. Misch, C.E., Maxillary sinus augmentation for endosteal implants: organized alternative treatment plans. *Int J Oral Implantol*, 1987. 4(2): p. 49-58.
4. Summers, R.B., The osteotome technique: Part 3—Less invasive methods of elevating the sinus floor. *Compendium*, 1994. 15(6): p. 698, 700, 702-4 passim, quiz 710.
5. Smiler, D.G., et al., Sinus lift grafts and endosseous implants. Treatment of the atrophic posterior maxilla. *Dent Clin North Am*, 1992. 36(1): p. 151-86, discussion 187-8.
6. Tatum, H., Jr., Maxillary and sinus implant reconstructions. *Dent Clin North Am*, 1986. 30(2): p. 207-29.
7. Trombelli, L., et al., Minimally invasive technique for transcrestal sinus floor elevation: a case report. *Quintessence Int*, 2010. 41(5): p. 363-9.
8. Stern, A. and J. Green, Sinus lift procedures: an overview of current techniques. *Dent Clin North Am*, 2012. 56(1): p. 219-33, x.
9. Pal, U.S., et al., Direct vs. indirect sinus lift procedure: A comparison. *Natl J Maxillofac Surg*, 2012. 3(1): p. 31-7.
10. Pozzi, A., et al., Flapless Transcrestal Maxillary Sinus Floor Elevation: computer guided implant surgery combined with expanding-condensing osteotomes protocol. *Oral Implantol (Rome)*, 2011. 4(1-2): p. 4-9.

*Sanjay Karunagaran, BDS, DDS, MSD, Assistant Professor and Prosthodontic Resident, Department of Prosthodontics, University of Tennessee Health Science Center College of Dentistry, Memphis, Tennessee. Contact Dr. Karunagaran at 901-448-6380 or*

*skarunaga@uthsc.edu*

*Jonathon Egbert, DDS, Prosthodontic Resident, Advanced Graduate Program in Prosthodontics, University of Tennessee Health Science Center College of Dentistry, Memphis, Tennessee.*

*Andrew Johnson, DDS, MDS, FACP, CDT, Prosthodontist, Adjunct Assistant Professor, University of Tennessee Health Science Center College of Dentistry, Memphis, Tennessee.*

*Sony C Markose, BDS, DDS, MSD, Prosthodontist, Private Practice, Carrollton, Texas. Former Assistant Director, Advanced Education in General Dentistry, Baylor College of Dentistry*

## Questions for Continuing Education Article - CE Exam #??

Publication date: Fall/Winter 2014. Expiration date: Fall/Winter 2017.

This exam is also available online. If you take the exam online, you can pay with a credit card and print out your certificate in a matter of minutes. Visit the TDAs website at [www.tenn dental.org](http://www.tenn dental.org)

1. Vertical ridge insufficiency near the maxillary sinus may be caused by all of the following except which one:
  - a. Trauma
  - b. Malocclusion
  - c. Posterior maxillary tooth extraction
  - d. Pneumatization of the maxillary sinus
2. Which is the most common procedure performed to increase bone volume in the maxillary sinus:
  - a. Indirect approach (Summer's)
  - b. Caldwell-Luc procedure
  - c. Direct lateral approach (Tatum)
  - d. Endoscopic sinus approach
3. Which of the following is an advantage of the Indirect/transcrestal approach when performing sinus augmentation:
  - a. Decreased post operative morbidity
  - b. Direct vision of the Schneiderian membrane
  - c. Quantity of augmented bone
  - d. Decreased occurrence of membrane perforation
4. A proposed tooth try-in was conducted to assess which of the following:
  - a. Ideal tooth positions
  - b. Phonetics
  - c. Esthetics
  - d. Vertical dimension of occlusion
5. At what depth should the osteotomy be prepared beneath the antral floor when performing the Indirect/transcrestal approach:
  - a. .5mm
  - b. 1.0mm
  - c. 1.5mm
  - d. 2.0mm

### ADA CERP Recognized Provider


*The Tennessee Dental Association is an ADA CERP Recognized Provider.*

*ADA CERP is a service of the American Dental Association to assist dental professionals in identifying quality providers of continuing dental education. ADA CERP does not approve or endorse individual courses or instructors, nor does it imply acceptance of credit hours by the boards of dentistry.*

*Concerns or complaints about a CE provider may be directed to the provider or to ADA CERP at [www.ada.org/goto/ceerp](http://www.ada.org/goto/ceerp)*

**ADA C.E.R.P.**® | Continuing Education  
Recognition Program

**Answer Form for TDA CE Credit Exam #??:**  
*Oral Complications of Cancer Therapy: A Summary Guide for the Clinician*  
 Publication date: Fall/Winter 2014. Expiration date: Fall/Winter 2017.



Circle the correct letter answer for each CE Exam question:

- |    |   |   |   |   |   |   |
|----|---|---|---|---|---|---|
| 1. | a | b | c | d |   |   |
| 2. | a | b | c | d | e |   |
| 3. | a | b | c | d | e | f |
| 4. | a | b | c | d | e | f |
| 5. | a | b | c | d |   |   |

Date exam taken: \_\_\_\_\_

**Please complete the following course evaluation. These answers do not affect the grading process.**

Assess your mastery of the material	<input type="checkbox"/> Full	<input type="checkbox"/> Partial	<input type="checkbox"/> No
Your comprehension of material	<input type="checkbox"/> Excellent	<input type="checkbox"/> Fair	<input type="checkbox"/> Poor
Appropriateness of the material	<input type="checkbox"/> Excellent	<input type="checkbox"/> Fair	<input type="checkbox"/> Poor
Was the material adequately in-depth?		<input type="checkbox"/> Yes	<input type="checkbox"/> No

*Additional feedback should be emailed to the TDA at [tda@tenndental.org](mailto:tda@tenndental.org)*

*Cost per exam per person is \$15.00. If you correctly answer four of the five questions, you will be granted one (1) continuing education credit. Credit may not apply toward license renewal in all licensing jurisdictions. It is the responsibility of each participant to verify the CE requirements of his or her licensing or regulatory agency. This page may be duplicated for multiple use. Please print or type.*

ADA ID Number (Dentist Only): \_\_\_\_\_

License Number of RDH: \_\_\_\_\_

Registration Number if RDA: \_\_\_\_\_

Name (Last/First/Middle): \_\_\_\_\_

Office Address: \_\_\_\_\_

City/State/Zip: \_\_\_\_\_

Daytime Phone Number : ( \_\_\_\_\_ ) \_\_\_\_\_

Component Society (TDA Member Only): \_\_\_\_\_

Dr. \_\_\_\_\_

(Auxiliary Staff: Please provide name of Employer Dentist)

All checks should be made payable to the Tennessee Dental Association. Return the Exam Form and your check or credit card information to:

**Tennessee Dental Association at 660 Bakers Bridge Ave., Suite 300 in Franklin, TN 37067**

*The form may be faxed to 615-628-0214 if using a credit card (use your TDA/Bank of America card, MasterCard or Visa ONLY):*

Signature: \_\_\_\_\_

Card #: \_\_\_\_\_ Exp. Date: \_\_\_\_\_

Three-digit CVV2 Code (on back of the card following the card number): \_\_\_\_\_

Name as it appears on the card: \_\_\_\_\_

**Do not write in this space - for TDA Administration purposes only**

Check #: \_\_\_\_\_ CC \_\_\_\_\_ Paid w/doctor's CC \_\_\_\_\_